

THE EVALUATION OF FUNCTIONAL OUTCOMES AFTER PLATE FIXATION OF MIDSHAFT FRACTURE OF CLAVICLE

Sonendra Kumar Sharma¹, R Bhalla², Sarabjeet Singh Sachdeva³, Rajat Chopra³

Received : 08/06/2023
Received in revised form : 03/07/2023
Accepted : 15/07/2023

Keywords:

Sepsis, SOFA Score, APACHE II, LACTATE, PCT, IL-6, and S. ferritin.

Corresponding Author:

Dr.Sonendra Kumar Sharma
Email: dr.sonendra@gmail.com

DOI: 10.47009/jamp.2023.5.4.114

Source of Support: Nil,
Conflict of Interest: None declared

Int J Acad Med Pharm
2023; 5 (4); 564-570



¹Assistant professor, Department of Orthopaedics, SRVS Medical Collage, Shivpuri, Madhya Pradesh, India.

²Senior Consultant & Former Chairman, Department of Orthopaedics, Sir Ganga Ram Hospital, New Delhi, India

³Senior Consultant, Department of Orthopaedics, Sir Ganga Ram Hospital, New Delhi, India.

Abstract

Background: The purpose of our study is to study the union and functional result of displaced clavicle fracture treated with plating and to study the complications associated with clavicle fracture and surgical management. **Methods:** We prospectively and retrospectively evaluated 29 patients who have undergone plating for midshaft clavicular fracture from Jan 2011 to Dec 2015. The data of prospective cases has been collected Data thus collected was analyzed using oxford shoulder score and radiological score. **Results:** All the fracture united and there is excellent functional outcome in 21 (72.41%) patients, good functional outcome in 5 (17.29%) patients and 3 (10.34%) patients had fair functional outcome. Out of 29 patients, 4 patients had plate prominence, 1 patients had hypertrophied skin scar, 1 patients had plate loosening, 1 patients had delayed union, 1 patients had deep infection in which later on plate exposed. All the patients were relatively satisfied with the treatment. **Conclusion:** In our we found that this technique provides a rigid stabilization of the fracture, leading to good fracture union. It also aids in an early mobilisation of shoulder, preventing its stiffness. The open reduction allows fracture approximation even in severe comminution. Primary open reduction and internal fixation with plate and screws of fresh Mid Shaft clavicle fractures provides a more rigid fixation and does not require immobilization for longer periods. Their outcome seems better than those reported with conventional conservative treatment. In this study early primary plate fixation of Mid Shaft clavicular fractures results in improved patient-oriented outcomes, improved surgeon-oriented outcomes, earlier return to function, and decreased rates of nonunion and malunion.

INTRODUCTION

Clavicle fracture is a common traumatic injury around shoulder girdle in young active individuals due to their subcutaneous position. The mechanism of injury is usually fall on to the outstretched upper extremity or direct blow or high velocity impact.^[1] Of all the fractures, clavicle fractures constitutes about 2.6%.^[2] and majority of them (80-85%) occurs in midshaft of the bone.^[3,4] Occasionally the bone will break where it attaches at the ribcage or shoulder blade.

Non-operative treatments were associated with 15-20% non-union and 1-5% malunion, because reduction is practically impossible to maintain, resulting

in disfigurement, sagging shoulder and weakness of shoulder.^[7] Even with advent of osteosynthesis fracture clavicle remained overlooked for centuries. It may have been because of its characteristic "S" shape.^[8] subcutaneous location, proximity to vital structures or difficulty in fixation due to unavailability of implants or it may be because of insignificant disability after conservative treatment. In females surgical scar over clavicle had cosmetic implications also.

In modern time the plate fixation has gained popularity, gives a good stable fixation, leading to early mobilisation of shoulder and ability to return back to work early.^[9]

But still there is no clear cut guidelines for operating clavicle fracture and controversy still continues, so this encouraged me to further elaborate this study to gain a deeper understanding of functional results and problems associated after fixation of mid shaft clavicular fractures.

Aims and Objectives

1. To study the union and functional results of displaced clavicle fracture treated with plating.
2. To study the complications associated with clavicle fracture and their surgical management.

MATERIALS AND METHODS

Place of Study

The study has been conducted at the Department of Orthopaedics of Sir Ganga Ram Hospital, New Delhi (SGRH). This is a 675 bedded super specialty hospital equipped with all the facilities for patient care as well as for research purposes.

Type of study

The study is prospective as well as retrospective, done at the Department of Orthopaedics at Sir Ganga Ram Hospital, Rajinder Nagar, New Delhi (SGRH)

Sample

Sample Size

Since this is an observational study so, all consecutive patients meeting the eligibility criteria during the study period has been enrolled. The prospective group includes 6 cases, who underwent surgery in our hospital, whereas 23 cases, who were operated previously constitute the retrospective group. We included retrospective cases as we couldn't find sufficient prospective cases to meet the sample size requirement.

Duration of study

The prospective study has been done from April 2015 to December 2015. For the retrospective group, cases operated between January 2011 to March 2015 were enrolled.

Subjects

Inclusion Criteria

1. Age >18years.
2. Displaced midshaft fractures.
3. Closed fractures.

Exclusion Criteria

1. Age < 18 years.
2. Open fractures
3. Associated head injury / neurovascular injury.
4. Established non-union from previous fracture.

Method of study

A prospective as well as retrospective study has been conducted in the Department of Orthopaedics at Sir Ganga Ram Hospital, New Delhi. A total of 29 patients admitted for fracture of displaced midshaft clavicle fracture and managed by plating have been evaluated in this study. The data of prospective cases has been collected from follow-up, serial radiographs and clinical assessment; whereas the data of the retrospective cases has been collected from Rec-

ord section of hospital and radiological department. The files and x-rays were collected. These patients were contacted on phone and were asked to come with old records for latest clinical and radiological follow-up and the deficit information was collected from the patient. Data thus collected was analyzed using oxford shoulder score[ANNEXURE-2] and radiological score[ANNEXURE-3].

Technique For Plate And Screw Fixation

Patient in supine position with one towel/small pillow in between the scapula. Entire upper limb from base of neck to hand were prepared and draped. About 7-9 cms, incision was made in the anterior aspect centering of clavicle over the fracture site. The skin subcutaneous tissue and platysma were divided without undermining the edges. The overlying fascia and periosteum were next divided. The osseous ends was freed from surrounding tissue. Minimal soft tissue and periosteum dissection was done. Fracture fragments were reduced and plate was applied over the superior aspect of the clavicle. At the junction of the medial and middle third of the clavicle, the inferior surface is exposed so that a protective instrument can be inserted during drilling to prevent injury to neurovascular structure underneath it. The plate was fixed to the medial and lateral fragment with 3.5mm cortical screw and atleast three screws in medial and lateral fragment were applied. Wound was closed in layers after ensuring meticulous hemostasis and sterile dressing was applied. 4,16,28,30,32

Post-Operative care

Patients were kept nil orally for 4 to 6 hours post-operatively. Intravenous fluids were given as needed. Antibiotics were continued for 7 days. Analgesics and tranquilizers were given according to the needs of the patient. The operated upper limb was immobilized in an arm pouch. Check x-rays were taken to study the alignment of fracture fragments. The wound was inspected at 3rd postoperative day. Suture removal was done on 14th postoperative day. Patients were discharged with the arm pouch. Rehabilitation of the affected arm was started at the end of 2 weeks. Gentle pendulum exercises to the shoulder in the arm pouch were allowed. At 4 to 6 weeks gentle active range of motion of the shoulder was allowed but abduction in limited to 80 degrees. At 6 to 8 weeks active range of motion in all planes were allowed.

Follow up

Regular follow up for every 4 weeks was done. Local examination of the affected clavicle for tenderness, instability deformity and shoulder movements were assessed. X-rays were taken at each follow up visits to know about progressive fracture union and implant position. Rehabilitation of the affected extremity were done according to the stage of fracture union and time duration from day of surgery. Patients were followed up till radiological union.

The functional outcome were assessed by Oxford Shoulder score and Radiological outcome by Radiological score.^[35,36]

RESULTS

The present study consists of 29 patients of comminuted mid shaft clavicle fracture where all patients were treated surgically with plating and screw between January 2011 to december 2015. All the patients were available for follow-up and they were followed every 6 weeks. Results were analyzed both clinically and radiologically.

Mode of Injury

In mid shaft clavicle fractures among them 8 patients (27.6%) were due to fall on shoulder from two wheeler, 19 patients (65.5%) were due to road traffic accident, in 2 patient (6.8%) it was due to assault.

Age Incidence

There is almost equal distribution in all age group of the patients with Mid Shaft Clavicle Fracture i.e. 10 patients (34.5%) in the age group of 20-29 years, 7 patients (24.1%) in the age group of 30-39 years, 4 patients (13.8%) in the age group of 40-49 and 8 patients (17.6%) in the age group of 50 or more. The youngest patient was 20 years and oldest patient was 69 years. The average patient age was 38 years.

Associated Injuries

In Mid Shaft Clavicle Fracture 5 patients (17.2%) had associated lower limb (femur and tibia fracture) injuries, 2 patient (6.8%) had associated upper limb injuries (radius and metacarpal fracture) and 4 patient (13.8%) had other injuries including spine fracture, facial injuries and abdominal injuries.

All the Patients were immobilized in an arm pouch.

Comminution

Plain radiograph of clavicle with shoulder is taken in anteroposterior view to assess the site of fracture and the type of fracture (like Displacement, Angulation, Comminution).

In this present study there were 29 patients (100%) of mid shaft clavicle fracture where 16 patients (55.2%) were having comminution at fracture site and 13 patients (44.8%) were having simple fracture pattern without any comminution.

All the patients in mid shaft clavicle fracture were closed type. There were no associated medical illness in any patient.

Major complication

A complication requiring inpatient treatment and resulting in an additional morbidity of 2 months or more was regarded as a major complication.

In Mid Shaft Clavicle Fracture fixation 4 patients (13.8%) plate prominence had occurred. In 1 patients (3.4%) infection (deep) occurred after 8 weeks of surgery, and after 10 weeks that plate was exposed on which later on implant removal was done

Table 1: Table 10: Showing distribution of complications

Types	No. of cases	%
Hypertrophic skin scar	1	3.4 %
Plate prominence	4	13.8 %
Infection (deep) & Exposed plate	1	3.4 %
Plate breakage	1	3.4 %
Delayed union	1	3.4 %

Functional Outcome

The functional outcome is assessed by Oxford Shoulder score.

In this study all of the 29 patients (100%) with Mid Shaft Clavicle Fracture had excellent functional outcome.

Table 11: Showing functional outcome

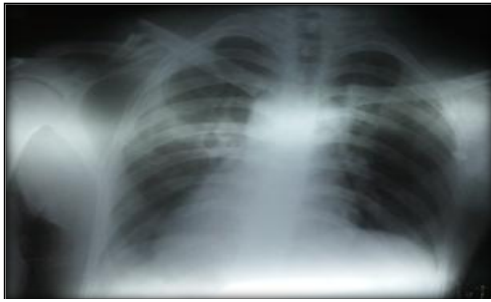
Functional outcome Total -48 points	Frequency	Percentage
Excellent (40-48)	21	72.4 %
Good (30-39)	5	17.2 %
Fair (20-29)	3	10.3 %
Poor (0-19)	0	0 %
Total	29	100 %

Radiographic Outcome

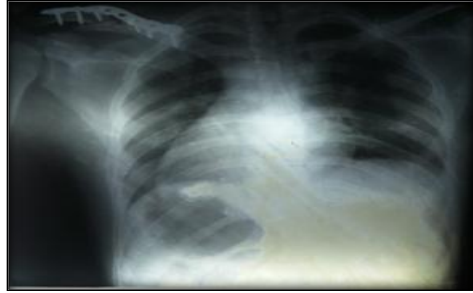In midshaft clavicle fracture treated surgically with plating, 24 patients (82.8%) united with radiographic grade-1 and 5 patients (17.2%) united with radiographic grade-2.

Table 12: Showing distribution of radiographic outcome

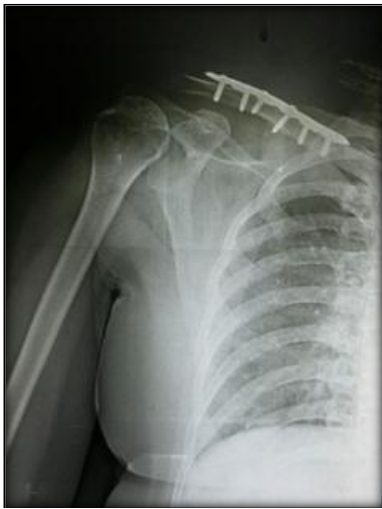Radiographic score	Frequency	Percentage
Grade-1	17	58.6 %
Grade-2	9	31.0 %
Grade-3	3	10.4 %
Grade-4	0	0 %
Total	29	100 %



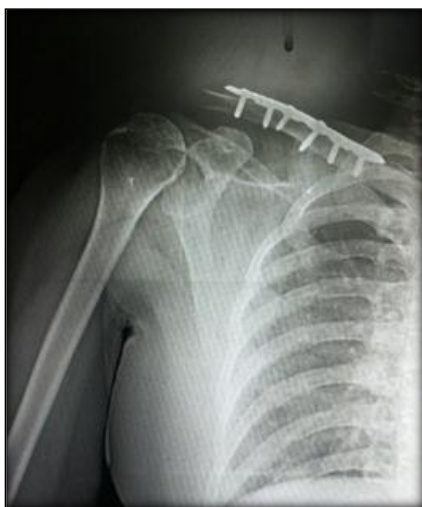PATIENTS X-RAY



Immediate post operative x-ray



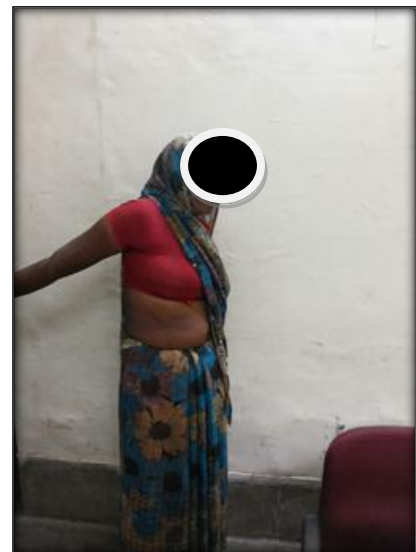6 weeks follow up x-ray



11 weeks x rays showing union



Flexion



Extension



Abduction

DISCUSSION

Clavicle fractures are usually treated conservatively. In a study conducted to analyze the results of conservative treatment by Hill et al.^[7] in 1997, Nordqvist et al.- in 1998 and Robinson et al.^[62] in 2004 found poor results following conservative treatment of displaced middle third clavicle fracture. Conservative treatment of displaced lateral third clavicle fracture has higher rate of non union and residual shoulder dysfunction as showed by Edwards et al.^[63] in 1992.

In our study we have done our evaluation and compared our results, with the similar other studies on midshaft clavicle fracture treated surgically with plating.

Mechanism of injury

In our study of mid shaft clavicle fractures among them 8 patients (27.6%) were due to fall on shoulder from two wheeler, 19 patients (65.5%) were due to road traffic accident, in 2 patient (6.8%) it was due to assault.

This is comparable with similar studies of Tsang et al.^[58] where 74% patients were of RTA, 8 patients of slipped down, 7 patients of sports injury and 6 patients of fall from height and by Dhoju et al (55) where 50% patients due to RTA, 45% patients due to fall from height, 5% patients due to buffalo assault, by Battacharya et al.^[61] where 50% cases of RTA and 50% cases of sporting injury or by direct violence and by Kulshrestha.^[51] in which 75% patients were due to RTA and 25% patients were due to fall from height.

Age Incidence

In the study there is almost equal distribution in all age group of the patients with Mid Shaft Clavicle Fracture i.e. 10 patients (34.5%) in the age group of 20-29 years, 7 patients (24.1%) in the age group of 30-39 years, 4 patients (13.8%) in the age group of 40-49 and 8 patients (17.6%) in the age group of 50 or more. The youngest patient was 20 years and oldest patient was 69 years. The average patient age was 38 years.

In Tsang et al.^[58] study average age was 45 years, in Dhoju et al.^[55] study average age was 31.5 years, in Battacharya et al.^[61] study it was 36.5 years and in Kulshrestha.^[51] study the average age was 31 years.

Associated injuries

In Mid Shaft Clavicle Fracture 5 patients (17.2%) had associated lower limb (femur and tibia fracture) injuries, 2 patient (6.8%) had associated upper limb injuries (radius and metacarpal fracture) and 4 patient (13.8%) had other injuries including spine fracture, facial injuries and abdominal injuries.

In similar study done by Tsang et al.^[58] 19 patients were having associated injuries such as multiple fractures, head injuries, rib fractures, hemopneumothorax, etc, in study of Dhoju et al.^[55] 5 patients (5%) had associated injuries, three had rib fracture and one had metacarpal and remaining one had tibia fracture and fracture of multiple phalanges of foot.



Adduction



External rotation



Internal rotation

Functional outcome:

In this study of the Mid Shaft Clavicle Fracture, 21 patients (72.41%) had excellent, 5 patients (17.29%) had good and 3 patients (10.34%) had fair functional outcome.

In similar study done by Tsang et al (58), 78 patients (95%) had an uneventful recovery with average DASH score of 26.35.

In Dhoju et al.^[55] study average Constant Score was 97.4 with SD 3.1 in one year follow up and all patients were relatively satisfied with the procedure.

In Kulshrestha.^[51] study as per Rowe Criterion 12 patients (60%) had excellent, 6 patients (30%) had good and 2 patients (10%) had fair results.

Radiographic Outcome

In this study all patients had satisfactory union, in 17 patients (58.6%) fracture united with Radiographic grade-1, in 9 patients (31.0%) fracture united with Radiographic grade-2 and in 3 patients (10.4%) fracture united with Radiographic grade -3 at final follow up of patients and there were no any nonunion noted in our study.

In Tsang et al.^[58] study 1.2% patient had nonunion with mean time to radiographic union was 11.2 weeks.

In Dhoju et al.^[55] study there was no nonunion or implant failure recorded.

In Battacharya et al.^[61] study, nonunion occurred in 2 patients (7.1%) and average time to union was 10 weeks.

Complications

Plate breakage

One patient (3.4%) plated with reconstruction plate for displaced and comminuted fracture was broken at 8 weeks postoperatively. Patients radiograph during the first follow up at 6 weeks showed reconstruction plate bending. In spite of advise the patient went for his regular occupation and involved in lifting heavy weight before radiological union of the fracture. At the end of 8 weeks postoperatively the reconstruction plate broke.

In Bostman et al.^[32] study 2 patients treated with semi tubular plate had implant breakage at 2nd and 7th postoperative weeks respectively. Both cases were treated by replating using dynamic compression plate with bone grafting.

Delayed union

Delayed union occurred in 1 patient (3.4%). In patient there was a large butterfly fragment in the inferior aspect of clavicle which went on to unite with the main fragments at the end of 14 weeks.

In another 1 patient (3.4%) delayed union occurred due to plate breakage at 8 weeks post operatively. Replating with bone grafting was done and it went on to unite at the end of 20 weeks postoperatively.

In Bostman et al.^[32] study delayed union occurred in 3 Patients (2.91%).

Deep infection

In this study 1 patient (3.4%) had deep infection after 8 weeks in the post operative period which was later on after 10 weeks exposed plate from the operative site, for which implant removal was done after

12 weeks. Even after infection and plate removal the fracture was united in this case.

This in comparison with Kao et al.^[64] study there was no complication in 11 patients (91.67%). In 1 patient (8.33%) had a fall at 2 months after operation. This patient received a revision surgery with distal clavicle resection and corococlavicular reconstruction.

Skin complications

There was cosmetically unacceptable skin scar in 2 patients (6.8%). Plate prominence through the skin was reported in 4 patients (13.8%). Among them all 6 patients (20.6%) had reconstruction plate fixation. The total complication in this study were 27.6% excluding skin related minor complications.

In similar study done by Tsang et al.^[58] 1 patient suffered from non-union with plate breakage, 1 suffered from refracture after plate removal, and 1 suffered from deep and another suffered from a superficial infection. The overall infection rate was 2.4%, and the non-union rate and refracture rate were both 1.2%.

In Dhoju et al.^[55] study, 1 patient had deep infection and 1 patient had frozen shoulder and there was no nonunion or implant failure.

In Battacharya et al.^[61] study, 1 patient (3.5%) developed deep wound infection which needed implant removal while 4 patient (14.2%) developed superficial infection which responded to intravenous antibiotics.

The advantage of rigid internal fixation and early mobilization of fresh displaced clavicle fracture is that it (displaced comminuted middle third and displaced lateral third clavicle fracture) gives immediate pain relief and prevents the development of shoulder stiffness and non-union.

CONCLUSION

This study is a prospective as well as retrospective evaluation of 29 cases of midshaft clavicle fractures treated surgically with plate fixation between January 2011 to December 2015 at Department of orthopaedics of Sir Ganga Ram Hospital, New Delhi.

Patients above 18 years were included in this study and the patients age ranged from 20 to 69 years. The average patient age was 38 years.

RTA & Fall from the two wheeler was the cause for this fracture in most of the patients. Males are more commonly affected. 37% of the patient had associated injuries like fracture shaft femur, fracture shaft tibia, mandible fracture, multiple ribs fracture, facial injury, abdominal injury.

In 20 patients (69%) surgery was done within the 1st week and 9 patients (31%) after 1st week. The indication for surgery in middle third clavicle fracture was displacement with comminution in 13 patients and displacement without comminution in 16 patients. All our patients were operated under general anesthesia with plate and screws.

Out of 20; in cases bone grafting was done due to severe comminution.

All our patients are immobilized in an arm pouch for 4 weeks. All the patients were mobilized at the end of 2nd week with the sling.

In Mid Shaft Clavicle Fracture fixation 4 patients (13.8%) plate prominence had occurred. In 1 patients (3.4%) infection (deep) occurred after 8 weeks of surgery, and after 10 weeks that plate was exposed on which later on implant removal was done. In that case too fracture united.

In this study on 29 patients (100%) with Mid Shaft Clavicle Fracture, which were treated surgically plate fixation had excellent functional outcome and good radiographic outcome at final follow up.

The functional outcome is assessed by Oxford Shoulder score. In this study all of the 29 patients (100%) with Mid Shaft Clavicle Fracture had excellent functional outcome with Oxford Shoulder Score ranging between 40-48.

Thus our study reveals that fixation of midshaft clavicle fracture by plating is a reliable modality of management. They provide better outcome in terms of fracture fixation, clinical and radiological union, early mobilization and overall an acceptable outcome.

The advantage of rigid internal fixation and early mobilization of fresh displaced clavicle fracture is that it (displaced comminuted middle third and displaced lateral third clavicle fracture) gives immediate pain relief and prevents the development of shoulder stiffness and non-union.

Recommendations

1. Displaced fracture of clavicle with or without comminution should be fixed, as it allows rigid fixation and early rehabilitation and return to work.
2. Chances of malunion, nonunion and prolonged immobilization are avoided.
3. We should exercise care in thin and skinny patients while plating as risk of skin dehiscence and prominent plate can cause problem.
4. Screws should be inserted under image intensifier guidance to avoid overlength screws, as it may damage surrounding neurovascular structures.
5. We recommend use of precontoured plates, which makes fixation easy.

REFERENCES

1. Stanley D, Trowbridge EA, Norris SH. The mechanism of clavicular fracture. A clinical and biomechanical analysis. *J Bone Joint Surg Br.* 1988;70:461-464.
2. Robinson CM. Fractures of the clavicle in the adult. Epidemiology and classification. *J Bone Joint Surg Br.* 1998;80:476-484.
3. Nordqvist A, Petersson C. The incidence of fractures of the clavicle. *Clin Orthop Relat Res.* 1994;300:127-132.
4. Craig EV. Fractures of the clavicle. In: Rockwood CA, Green DP, Bucholz RW, Heckman JD, eds. *Rockwood and Green's Fractures in Adults.* Philadelphia: Lippincott-Raven, 1996:1109-1161.
5. Hill JM, McGuire MH, Crosby LA. Closed treatment of displaced middle-third fractures of the clavicle gives poor results. *J Bone Joint Surg Br.* 1997;79:537-539.
6. Moseley HF. The clavicle: its anatomy and function. *Clin Orthop* 1968;58:17-27.
7. Zlowodzki M, Zelle BA, Cole PA. Treatment of midshaft clavicle fractures: systemic review of 2144 fractures. *J Orthop Trauma.* 2005;19:504-507.
8. Taitzman L, Nork SE, Coles CP, et al. Open fractures of the clavicle and associated injuries. *J Orthop Trauma* 2006;20:369-399.
9. Grassi FA, Tajana MS, D'Angelo F. Management of midclavicular fractures: comparison between nonoperative treatment and open intramedullary fixation in 80 patients. *J Trauma* 2001;50:1096-1100.
10. Moore TO. Internal pin fixation for fracture of the clavicle. *Ann Surg* 1951;17:580-583.
11. Bostman O, Manninen M, Pihlajamaki H. Complications of plate fixation in resh displaced mid clavicular fractures. *J Trauma,* 1997; 43:778-783.
12. Gaudinez RF, Hoppenfeld S. Clavicle fractures. Chapter-10 In : Hoppenfeld S,
13. Murthy VL, editors. *Treatment and Rehabilitation of fractures,* Philadelphia:
14. Lippincott Williams and Wilkins, 2000 ;73-84.
15. Rabe SB, Oliver GD. Clavicular fracture in a collegiate football player. A case report of rapid return to play. *Journal of Athletic Training.* 2011.46(1).107-111.
16. Kulshrestha V. Primary plating of displaced mid-shaft clavicular fractures. *Medical journal armed forces india.* 2008: 64 :208-211.
17. Dhoju D, Shrestha D, Parajuli NP, Sharma V. Operative fixation of displaced middle third clavicle (edinberg typr 2) fracture with superior reconstruction plate osteosynthesis. *Kathmandu Univ Med J.* 2011: 36(4) :286-91.
18. Tsang D, Cheng CW, Leung LFM, Shen PW, Lin HT. Open-reduction internal fixation of a displaced clavicle fracture with a 3.5 mm reconstruction locking plate : Does a titanium reconstruction plate provide better outcomes ?. *Fu-Jen Jo-urnal of Medicine.* 2012 : 3 : 119-126.
19. Battacharya A, Sarkar S. Plate fixation of fresh displaced midshaft clavicular fractures. *J of Evidence Based Med and Hithcare.* 2015 : 2 : 342-345.
20. Robinson CM, Court Brown CM, McQueen MM, Walkefield AE. Estimating the risk of non union following non operative treatment of a clavicular fracture. *J Bone Joint Surgery (Am).* 2004 :86 :1359-1365.
21. Edwards DJ, Kavanagh TG, Flannery MC. Fractures of the distal clavicle a case for fixation. *Injury.* 1992 : 23 : 44-46.
22. Kao FC, Chao E K, chen CH, Yu SW, Chen CY, Yen CY. Treatment of distal clavicle fracture using Kirschner wire and tension band wires. *J.Trauma.* 2001 : 51: 522-525.